Common Eye Issues in Mice and Rats – Decision Making Tree

START

Is the eye present and normal sized?

- Not present → Anophthalmia – no eye present (Fig 1)
- Small → Microphthalmia – eye is small (Fig 2)

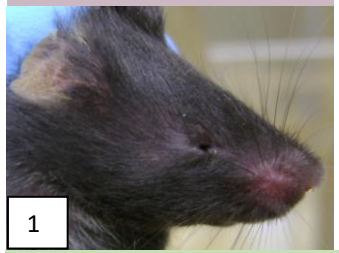

If no other issues present then these mice can still be used.
DO NOT BREED from these mice as these conditions are genetically linked

Yes → Is there evidence of inflammation?
For example swollen or red eyelids, hair loss around the eye, wounds around the eye (Fig 3 + 4)

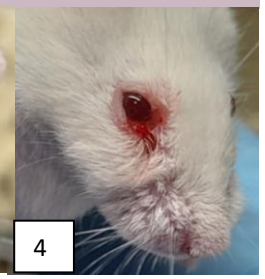

Yes → Is there damage to the surface of the eye?

- Unsure → Apply a drop of fluorescein to the eye (Fig 6)

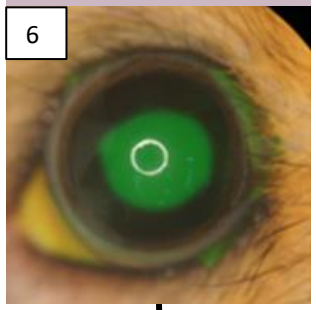

Is there stain uptake? (as in Fig 6)

- No → Conjunctivitis (Fig 5)

Treat with Maxitrol
Give twice daily for 3 days
NOTE: do not use Maxitrol if there is risk of ocular damage

- Yes → Corneal ulcer (Fig 7 + 8)

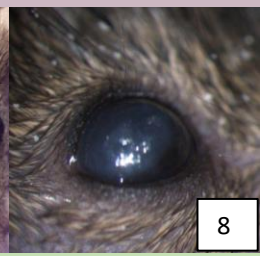

Treat with Isathal (or other antibiotic) and corneal repair gel.
Give twice daily for 3 days

- Yes → Severe → Severe deformity of the eye (Fig 9)

Cull

No → Is there discharge around the eye without inflammation?

- Yes → Porphyrin staining (Fig 10)

Sign of stress, try to identify and remove the stressor

- No → Is there change to the normal colour of the eye?
  - Yes → Surface of eye → Clouding or deposit (Fig 11)



  - Yes → Beneath surface → Cataract (Fig 12)



Monitor if no other concerns

- If the issue you have identified does not match these examples or you are unsure contact your NVS for further advice.
- Make sure to contact the user prior to undertaking any treatment to ensure treatment can be given.
- Notify the NVS of the eye issue and the intervention that will be provided via email or during a unit visit – they will respond if they would like you to do something different
- If after 3 days of treatment the issue is not fully resolved, discuss next steps with the NVS